

## “Effect of Rosiglitazone alone and in combination with Sulfasalazine in experimentally induced inflammatory bowel disease in rats”

Shivashankar P<sup>1,\*</sup>, Purushotham K<sup>2</sup>, Mangala Lahkar<sup>3</sup>

<sup>1</sup>Manager, Medical Affairs & Pharmacovigilance, Ecron Acunova Limited, Bangalore, <sup>2</sup>Assistant Professor, Sri Siddhartha Medical College, Tumakuru, Karnataka, <sup>3</sup>Professor & Head, Dept. of Pharmacology, Gauhati Medical College & Hospital, Guwahati

\*Corresponding Author:

Email: amrushi@gmail.com

### Abstract

**Background:** Inflammatory bowel disease (IBD) is an idiopathic, chronic inflammatory condition, which affects the gastrointestinal tract and has no curative treatment. The present study aimed to investigate the effect of different doses of Rosiglitazone alone and in combination with sulfasalazine in AA (acetic acid)-induced inflammatory bowel disease (IBD) in rats.

**Methods:** A total of 36 animals were included in the study. Animals were divided into five groups (n = 6): group I - control (normal saline), group II-AA+ normal saline, group III-Sulfasalazine(360mg/kg) +AA, group IV A - Rosiglitazone (1 mg/kg), group IV B- Rosiglitazone 5 mg/kg + AA, group V - Rosiglitazone 5 mg/kg + Sulfasalazine (360 mg/kg) +AA. Group IV was divided into two subgroups, namely IVA and IVB, on the basis of different doses of Rosiglitazone used. After completion of one week of treatment, rats were sacrificed under ether anesthesia for assessment of intestinal inflammation using parameters namely colon weight change, macroscopic and histopathological evaluation.

**Results:** There was a decrease in colonic weight, macroscopic scores and microscopic scores in groups treated with Rosiglitazone at a dose of 5 mg/kg i.e. high dose given alone and in combination with sulfasalazine. Combination treatment was more effective when compared to single drug treatment.

**Conclusion:** The present study indicates the efficacy of Rosiglitazone in Acetic acid-induced IBD. The effects are more pronounced at higher dose i.e., 5 mg/kg. Combination of Rosiglitazone and Sulfasalazine has shown greater efficacy than single drug treatment.

**Keywords:** Inflammatory bowel disease, Rosiglitazone, Colon weight change, Macroscopic evaluation, Histopathological evaluation

### Access this article online

**Website:**

[www.innovativepublication.com](http://www.innovativepublication.com)

**DOI:**

10.5958/2393-9087.2016.00025.X

### Introduction

Inflammatory bowel disease (IBD) is an immune-mediated chronic intestinal condition. Ulcerative colitis (UC) and Crohn's disease (CD) are the two major types of IBD. The incidence of IBD, especially UC, is rising in Japan, South Korea, Singapore, northern India and Latin America, areas previously thought to have low incidence.<sup>1</sup>

Patients with CD and UC alternate between periods of active disease, which may require hospital admission, and periods of remission. The cause of IBD seems to include genetic, environmental, and immunologic components. Evidence suggests that IBD is triggered by an aberrant immune response to enteric flora, leading to intestinal inflammation.<sup>2,3</sup>

Pathophysiological changes in IBD are well established, among which cytokines like tumor necrosis factor  $\alpha$  (TNF-  $\alpha$ ), interleukin-1 (IL-1) and interleukin-8 (IL-8) are secreted from macrophages.<sup>4</sup> TNF-  $\alpha$  upregulates the adhesion molecules (E selectin and

ICAM-1) causing the adherence of neutrophils in endothelium and passage into the bowel wall. Release of IL-8 attracts the activated neutrophils, and causes degranulation of the toxic proteases and other reactive oxygen species, which are cytotoxic and cause ulceration of intestine.<sup>4</sup> Frontline drugs that are currently used to treat IBD includes 5-aminosalicylic acid (sulfasalazine), corticosteroids (prednisolone), immunomodulatory drugs (azathioprine, mercaptopurine, methotrexate), IgG anti-TNF $\alpha$  antibody (infliximab) and antibiotics (metronidazole, ciprofloxacin).<sup>5</sup> These drugs have varying efficacy from patient to patient, and long-term use of these drugs can have harmful side effects. In view of the devastating nature of IBD and the limited efficacy of the drugs used for its treatment, it would be very helpful to have other effective anti-inflammatory drugs.

The peroxisome proliferator-activated receptors (PPARs) are a family of ligand-activated transcription factors that are members of the nuclear receptor superfamily.<sup>6</sup> The 3 members of this family are PPAR- $\gamma$ , PPAR  $\alpha$ , and PPAR  $\delta$ . The PPARs form obligate heterodimers with retinoid X receptors, which bind to a peroxisome proliferator response element and activate the transcription of target genes. PPAR- $\gamma$  is highly expressed in fat and plays an important role in activating genes that regulate adipocyte differentiation. PPAR- $\gamma$  is also the molecular target for the thiazolidinedione (TZD) insulin-sensitizing drugs Rosiglitazone and Pioglitazone,

which are currently in use for the treatment of type II diabetes mellitus.<sup>6</sup> in the immune system, PPAR- $\gamma$  is expressed in activated macrophages, dendritic cells, T lymphocytes, and B lymphocytes. PPAR- $\gamma$  ligands have anti-inflammatory activity that is attributable to effects in these cells.<sup>7-9</sup> In addition to inflammatory cells, PPAR- $\gamma$  is expressed at high levels in colonic epithelial cells where it has been proposed that it plays important roles in the differentiation of these cells as they migrate from the crypt base to the surface.<sup>10-14</sup> Thus, PPAR- $\gamma$  is an attractive target for the treatment of IBD, which is characterized by both inflammation and abnormalities in epithelial proliferation, differentiation, and function.

So the present study was conducted to evaluate the effect of different doses of Rosiglitazone alone and in combination with sulfasalazine in experimentally induced inflammatory bowel disease in rats.

## Methods

**Materials:** The present study was conducted in the Department of Pharmacology, Gauhati Medical College, Guwahati. The anti-inflammatory effect of Rosiglitazone alone and in combination with sulfasalazine was studied in experimentally induced inflammatory bowel disease in albino rats.

**Experimental animals:** Adult Wistar albino rats of either sex weighing between 150-250 gm were procured from the institute central animal house. The animals were housed in standard laboratory conditions at 25°C and 12 hours light and dark cycle. Animals were given free access to rat chow diet and water ad libitum. Before conducting experiments animals were acclimatized to laboratory conditions for seven days.

**Drugs and chemicals:** Drugs and chemicals needed for the study are sulfasalazine (Cadila), acetic acid (AA) and Rosiglitazone (Ranbaxy).

**Ethical review:** Experimental protocol was approved by the Institutional Animal Ethics Committee (IAEC) of Gauhati Medical College, Guwahati (IAEC No: 351/CPCSEA/3/1/2001). The study was performed in accordance to the CPCSEA guidelines.

### Dose and route of administration

- Sulfasalazine – 360mg/kg per oral (P.O)<sup>15</sup>
- Rosiglitazone – 1mg/kg and 5mg/kg (P.O)<sup>16</sup>
- Acetic acid – 1ml of 4% transrectally (T.R)

## Methods

Total 36 animals were included in the study. Animals were divided into five groups I, II, III, IV and V. Group IV was subdivided into two subgroups A and B. Each group and subgroup will have six animals.

Groups were:

Group I - Control group

Group II - Acetic acid treated group

Group III - Positive control group - Sulfasalazine (360mg/kg) + 4% AA

Group IV - Test group (Rosiglitazone + AA)

Group IV Sub group A - Rosiglitazone (1mg/kg) + 4% AA

Group IV Sub group B - Rosiglitazone (5mg/kg) + 4% AA

Group V - Sulfasalazine (360mg/kg) + Rosiglitazone (5mg/kg) + 4% AA

## Induction of colitis

IBD was induced according to the procedure described by MacPherson and Pfeiffer.<sup>17</sup> Briefly, rats were slightly anaesthetized with ether following 24hr fast, a soft 6F pediatric catheter lubricated with lignocaine jelly was inserted rectally into the colon through anus such that tip is 8cm proximal to anus, approximately at the splenic flexure. Then 1 ml 4% acetic acid was introduced into the colon and, after 30s of exposure, the fluid was withdrawn. As previously shown, an intrarectal administration of 4% acetic acid produces colonic inflammation in rats that resembles many histological characteristics of human ulcerative colitis.<sup>18</sup>

The experimental animals were divided into mainly 5 groups.

Group I: (Normal saline treated group) in this group 1ml of normal saline was delivered intrarectally to the rats after ether anesthesia as method described earlier.

Group II: (Acetic acid treated group) 1ml of 4% acetic acid was delivered intrarectally to the rats after ether anesthesia as mentioned earlier to induce colitis.

Group III: (Sulfasalazine treated group) Rats received sulfasalazine 360mg/kg of rat body weight, orally daily by intra-gastric tube for 7days. On 7th day, 1hr after sulfasalazine administration rats was given 1ml of 4% acetic acid intrarectally after ether anesthesia.

Group IV: (Rosiglitazone treated group) Animals were divided into two subgroups on the basis of different doses. Total 12 rats were included in this group. Each group had six animals.

Group IV sub group A: Rosiglitazone in the dose of 1 mg/kg body weight of rat was given orally once daily by intra-gastric tube for 7days. On the 7th day, 1hr after Rosiglitazone administration rats was given 1ml of 4% acetic acid intrarectally after ether anesthesia.

Group IV sub group B: Rosiglitazone in the dose of 5 mg/kg body weight of rat was given orally once daily by intra-gastric tube for 7days. On the 7th day, 1hr after Rosiglitazone administration rats was given 1ml of 4% acetic acid intrarectally after ether anesthesia.

Group V (Sulfasalazine and Rosiglitazone combination treated group) Rats received combination of sulfasalazine 360mg/kg body weight of rat orally daily with Rosiglitazone 5 mg/kg (most effective dose found in group IV), orally once daily by intra-gastric tube for 7days. On 7th day, 1hr after combination treatment, rats received 1ml of 4% acetic acid intrarectally after ether anesthesia.

**Assessment of Colonic Damage:** The parameters assessed were colon weight change, macroscopic evaluation and histopathological evaluation and given macroscopic and microscopic score. The assessment was carried out in the Department of Pathology, Gauhati Medical College and Hospital.

**Colon weight change:** The weight of damaged colon tissue is considered an indicator of the severity and extent of inflammatory response, where an increase in colonic weight represents inflammation and a decrease in colonic weight following treatment indicates anti-inflammatory activity.

**Macroscopic evaluation:** Twenty-four hours following induction of colitis, animals were euthanized by ether and 10cm of distal colon was removed from surrounding tissues, opened longitudinally along its mesenteric border, rinsed, and processed for histology. After washing the mucosa with saline solution, mucosal injury (macroscopically) was assessed using the grading scale of Morris et al. (1989).<sup>19</sup>

Score 0 – No damage

Score 1 – localized hyperemia but no ulcers

Score 2 – linear ulcers with no significant inflammation

Score 3 – linear ulcer with inflammation at one site

Score 4 – two or more sites of ulceration and inflammation

Score 5 – two or more sites of ulceration and inflammation or one major site of Inflammation and ulceration extending >1cm along the length of the colon.

**Histopathological evaluation:** Additional samples were fixed in 10% formalin in phosphate buffered saline, embedded in paraffin, and cut into 4µm sections. Paraffin sections were deparaffinized with xylene, hydrated, and stained with hematoxylin and eosin. The degree of inflammation was graded semi quantitatively from 0 to 11 as the sum of:<sup>20</sup>

- Loss of mucosal architecture (score 0–3)
- Cellular infiltration (score 0–3)
- Muscle thickening (score 0–3),
- Crypt abscess formation (score 0–1)
- Goblet cell depletion (score 0–1)

### Statistical analysis

All the data were entered in to data base program. Data were expressed as mean ± SEM. Results were analyzed by one way analysis of variance (ANOVA), followed by Dunnet's multiple comparison test. P value <0.05 was considered as statistically significant.

### Results

**Colon weight changes:** Mean colonic weight of group I was  $4.38 \pm 0.18$  which is statistically significant ( $p < 0.01$ ) when compared to group II with a mean colonic weight of  $9.67 \pm 0.22$ . (Table 1, Figure 1A) Mean colonic weight of group III was  $4.74 \pm 0.08$  which was statistically significant ( $p < 0.01$ ) when compared with group II. In case of animals pretreated with rosiglitazone

at a dose of 5mg/kg (group IV B), mean colonic weight was  $7.11 \pm 0.07$  which was statistically significant ( $p < 0.05$ ) when compared to the group II. But animals pretreated with rosiglitazone at a dose of 1mg/kg (group IV A), mean colonic weight was  $8.91 \pm 0.17$ , which when compared to group II was statistically not significant ( $p > 0.05$ ). Whereas in animals pretreated with combination of sulfasalazine with rosiglitazone 5mg/kg (group V), mean colonic weight was  $5.48 \pm 0.17$  which was statistically significant compared with the group II ( $p < 0.01$ ).

**Macroscopic evaluation:** Mean values of macroscopic score of group I was  $0.33 \pm 0.21$  which is statistically significant ( $p < 0.01$ ) when compared group II with a score of  $4.83 \pm 0.16$ . (Table 1, Figure 1B) Mean macroscopic score of group III was  $1.67 \pm 0.21$  which is statistically significant ( $p < 0.01$ ) when compared with group II. In case of animals pretreated with rosiglitazone at a dose of 5mg/kg (group IV B), mean macroscopic scoring was  $3.75 \pm 0.21$  which is statistically significant ( $p < 0.05$ ) when compared to the group II. But animals pretreated with rosiglitazone at a dose of 1mg/kg (group IV A), mean macroscopic score was  $4 \pm 0.25$ , which when compared to group II is statistically not significant ( $p > 0.05$ ). Whereas in animals pretreated with combination of sulfasalazine with rosiglitazone 5mg/kg (group V), mean macroscopic score was  $2 \pm 0.25$  which is statistically significant compared with the group II ( $p < 0.01$ ).

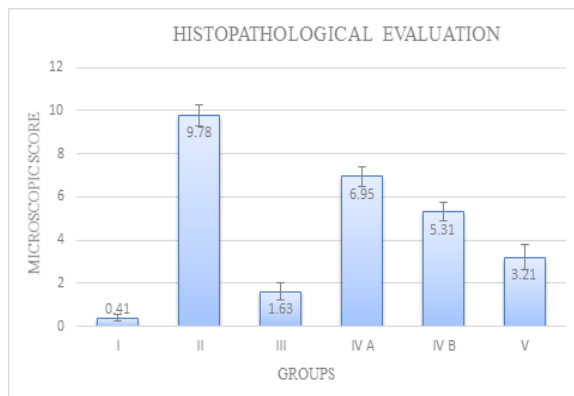
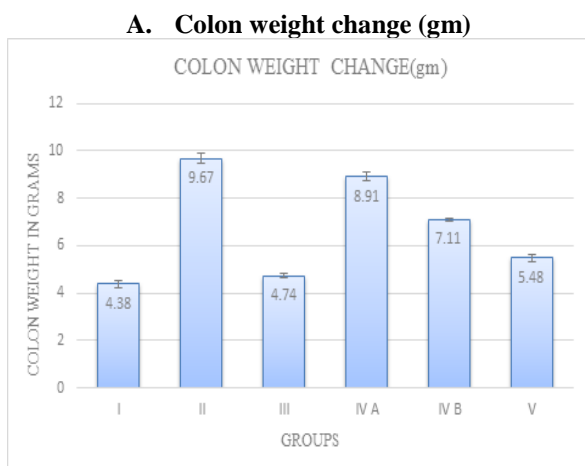
**Histopathological evaluation:** Mean values of microscopic score of group I was  $0.41 \pm 0.16$  which is statistically significant ( $p < 0.01$ ) when compared to group II with a score of  $9.78 \pm 0.50$ . (Table 1, Fig. 1C) Mean microscopic score of group III was  $1.63 \pm 0.42$  which is statistically significant ( $p < 0.01$ ) when compared with group II. In case of animals pretreated with rosiglitazone at a dose of 5mg/kg (group IV B), mean microscopic scoring was  $5.31 \pm 0.41$  which is statistically significant ( $p < 0.05$ ) when compared to the group II. But animals pretreated with rosiglitazone at a dose of 1mg/kg (group IV A), mean microscopic score was  $6.95 \pm 0.45$ , which when compared to group II is statistically not significant ( $p > 0.05$ ). Whereas in animals pretreated with combination of sulfasalazine with rosiglitazone 5mg/kg (group V), mean microscopic score was  $3.21 \pm 0.60$  which is statistically significant compared with the group II ( $p < 0.01$ ). (Fig. 2)

Thus from the above results, it is seen that Rosiglitazone at a dose of 5 mg/kg i.e. high dose given alone and in combination with sulfasalazine reduced colon weight and decreased macroscopic and microscopic score significantly. Combination treatment was more effective in decreasing microscopic damage score when compared to single drug treatment. Both combination treatment group and single drug treatment group were equally or less effective in decreasing microscopic damage score when compared with standard drug sulfasalazine.

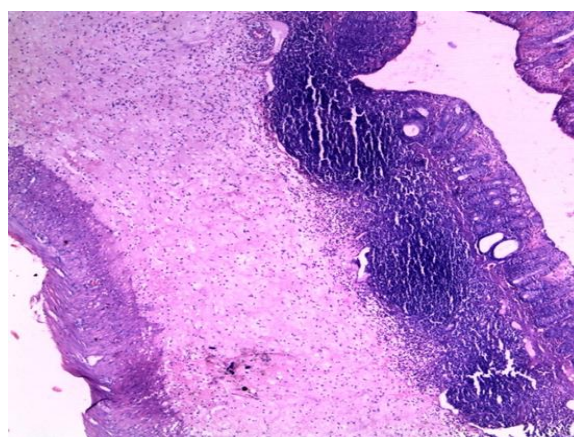
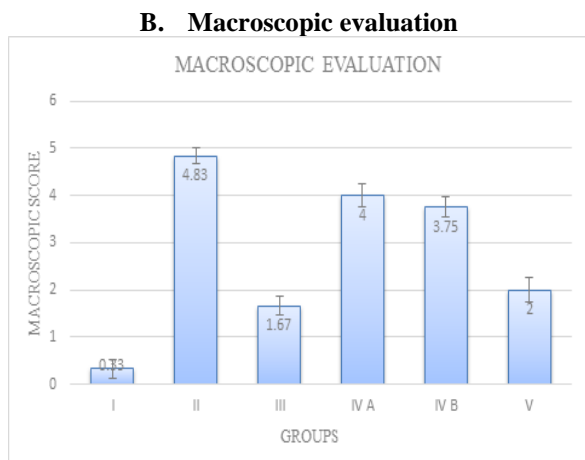
**Table 1: Showing parameters for assessment of colonic inflammation**

Groups	Treatment	Colon weight change (gm)	Macroscopic score	Microscopic score
I	Normal saline	4.38±0.18*	0.33±0.21*	0.41±0.16*
II	AA treated	9.67±0.22	4.83±0.17	9.78±0.50
III	Sulfasalazine + AA	4.74±0.08*	1.67±0.21*	1.63±0.42*
IV A	Rosiglitazone (1mg/kg) + AA	8.91±0.17 <sup>+</sup>	4±0.25 <sup>+</sup>	6.95±0.45 <sup>+</sup>
IV B	Rosiglitazone (5mg/kg) + AA	7.11±0.07 <sup>#</sup>	3.75±0.21 <sup>#</sup>	5.31±0.41 <sup>#</sup>
V	Sulfasalazine + Rosiglitazone(5mg/kg) + AA	5.48±0.17*	2±0.25*	3.21±0.60*

Data are expressed as mean ± SEM (n=6) and analyzed using one way ANOVA followed by Dunnett’s t test. The statistical significance was considered as significant if \* p < 0.01, # p < 0.05, + p < 0.05 when compared with acetic acid group.



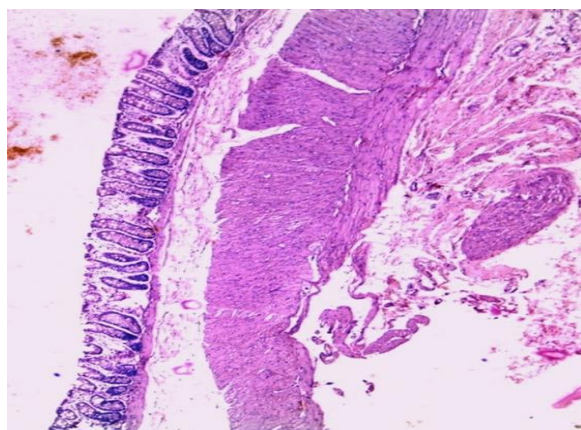
**Fig. 1: Effect of different doses of Rosiglitazone alone and in combination with Sulfasalazine on parameters of colonic inflammation in experimentally induced inflammatory bowel disease in rats.**



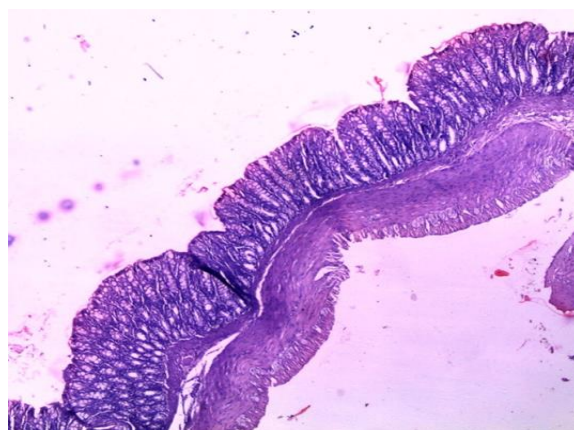**A**

**C. Histopathological evaluation**

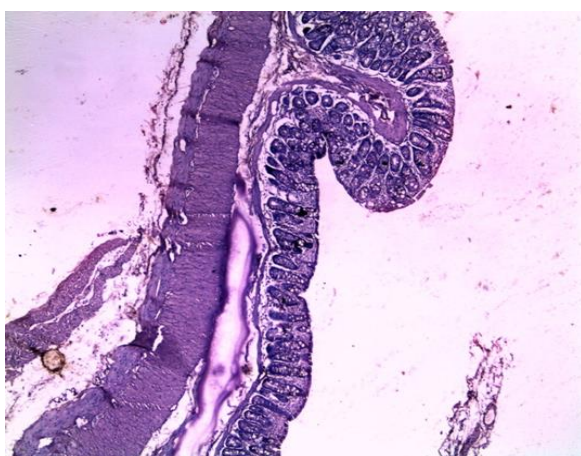




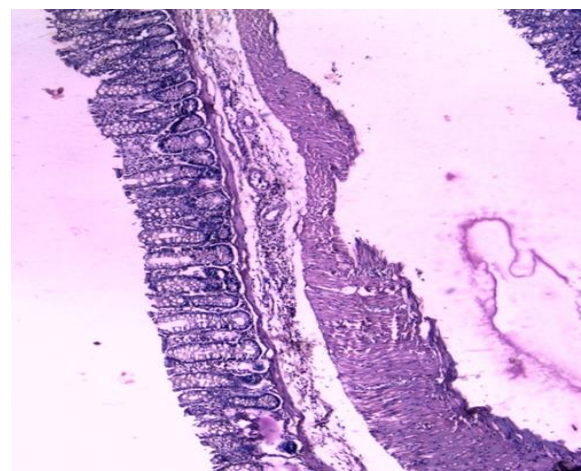
B



E



C



D

**Fig. 2: Histopathological sections of colons from rats stained with H&E**

Colonic microscopic image of [A] Normal rat colon from Control group I with intact mucosal layer and epithelial; [B] AA treated (group II) rat colon with diffused active colitis, extensive damage including edema of mucosa and submucosa and chronic inflammatory cells infiltrate with widely ulcerating mucosa, and hemorrhages; [C] Sulfasalazine treated (group III) colon with reduced active colitis, reduced mucosal ulcer and minimal inflammatory cell infiltrates; [D] Rosiglitazone 5mg/kg(group IV B) treated colon showing reparative epithelial changes and ulcer healing with lymphoid follicle in colon; [E] attenuated cell damage with minimal cell infiltrates and improved ulcer healing in group treated with combination of Sulfasalazine and Rosiglitazone 5mg/kg (group V).

### Discussion

Inflammatory bowel diseases (IBD) including ulcerative colitis (UC) and Crohn's disease (CD) are amongst the most challenging human illness in the world. Inflammatory mediators such as cytokines, eicosanoids and reactive oxygen metabolites play a crucial role in the development and persistence of this disease.

Recently, rosiglitazone has been implicated in the control of inflammatory process in several in vitro and in vivo models of inflammation other than IBD. Thus the present study was carried out with an attempt to evaluate the anti-inflammatory effect of rosiglitazone alone and in combination with sulfasalazine in acetic acid induced inflammatory bowel disease in albino rats.

Induction of colitis in rats using acetic acid is a classical method used to produce an experimental model of human IBD. Several major causative factors in the initiation of human colitis such as enhanced vasopermeability, prolonged neutrophils infiltration, and increased production of inflammatory mediators are involved in the induction of this animal model.<sup>21</sup> Acetic acid affects the distal colon portion and induces non-transmural inflammation, massive necrosis of mucosal

and submucosal layers, mucosal edema, neutrophil infiltration of the mucosa and submucosal ulceration. The protonated form of the acid liberates protons within the intracellular space and causes a massive intracellular acidification resulting in massive epithelial damage. The inflammatory response initiated by acetic acid includes activation of cyclooxygenase and lipoxygenase pathways.<sup>22</sup>

Rosiglitazone was given in the dose of 1mg/kg and 5mg/kg body weight by gastric lavage. The standard drug sulfasalazine was given in the dose of 360mg/kg body weight by gastric lavage and colitis was induced in experimental animals by giving 1ml of 4% acetic acid intrarectally.

The parameters assessed were colon weight change, macroscopic evaluation and histopathological evaluation and given macroscopic and microscopic score.

The weight of damaged colon tissue is considered an indicator of the severity and extent of inflammatory response. The effect of the drugs on colonic weight following acetic acid induced colitis was determined, where an increase in colonic weight represents inflammation and decrease in colonic weight indicates anti-inflammatory activity. There was a decrease in colonic weight in groups treated with Rosiglitazone at a dose of 5mg/kg i.e. high dose given alone and in combination with sulfasalazine. The macroscopic scores and microscopic score were less in groups treated with Rosiglitazone at a dose of 5mg/kg i.e. high dose given alone and in combination with sulfasalazine. But combination treatment was more effective in decreasing colon weight, macroscopic and microscopic score when compared to single drug treatment. Both combination treated group and single drug treated group when compared with standard drug sulfasalazine are equally or less effective.

Our study correlates well with the study by Hidalgo MS et al,<sup>23</sup> where colon weight, microscopic and macroscopic score decreased significantly following administration of rosiglitazone.

Therefore from the results seen so far it can be said that this study tentatively draws the inference that rosiglitazone in high doses possess anti-inflammatory activity against experimentally induced inflammatory bowel disease.

There are quite convincing data in favor of beneficial effects of rosiglitazone in inflammatory diseases.

Ashraf Taye et al,<sup>24</sup> has shown role of rosiglitazone as a gastro protective agent against indomethacin-induced gastric mucosal injury in rats. The antioxidant properties of rosiglitazone seem to play a crucial role in the gastro protection via scavenging free radicals. As mentioned earlier free radical scavenging is one of the factors in development of inflammatory bowel disease, rosiglitazone protected the colonic mucosa from damage probably by scavenging free radicals.

Priya Movants et al,<sup>25</sup> has shown rosiglitazone to cause a rapid and consistent suppression of intranuclear content of the proinflammatory transcription factor NF- $\kappa$ B, which regulates the expression of some important rapid-acting genes involved in the early inflammatory response to harmful stimuli. From a therapeutic viewpoint, some of these gene products are candidates for targeting in case of inflammatory conditions. Thus in present study, rosiglitazone may have protected the colonic damage by suppressing NF- $\kappa$ B expression.

A study by Demirturk F et al,<sup>26</sup> has shown anti-inflammatory activity of rosiglitazone in the prevention of intra-abdominal adhesion formation in a rat uterine horn model which is due to inhibition of cytokine production. As mentioned earlier cytokine production is one of the mechanism in development of IBD, rosiglitazone by its cytokine inhibition property has protected colonic mucosa from damage.

In experimental autoimmune encephalomyelitis reported by Diab A et al,<sup>27</sup> which is an animal model of Multiple sclerosis (MS), rosiglitazone suppressed T-cell activation. T-cell activation is an important pathogenesis for IBD. Rosiglitazone has protected against IBD by suppressing T-cell activation.

Intraperitoneal administration of the PPAR $\gamma$  ligands 15d-PGJ2 and troglitazone ameliorated adjuvant-induced arthritis with suppression of pannus formation and mononuclear cell infiltration in rats.<sup>28</sup> The anti-inflammatory activity of thiazolidinediones against adjuvant induced arthritis in mice was secondary to the inhibition of NF- $\kappa$ B pathway. Rosiglitazone being a PPAR $\gamma$  agonist has a role in suppression of mononuclear cell infiltration in colonic mucosa by inhibition of NF- $\kappa$ B pathway.<sup>29</sup>

Thus from the above discussion it is seen that rosiglitazone in a dose of 5mg/kg has significant anti-inflammatory effect. Rosiglitazone (5mg/kg) when combined with sulfasalazine, a reference standard drug has shown to improve colonic mucosal damage significantly. And also from the above discussion it can be seen that rosiglitazone has anti-inflammatory effect in colonic mucosa by more than one mechanism.

## Conclusion

The present study indicates the efficacy of Rosiglitazone in Acetic acid-induced IBD. The effects are more pronounced at higher dose i.e., 5 mg/kg. Combination of Rosiglitazone and Sulfasalazine has shown greater efficacy than single drug treatment. These findings however needs further confirmation in human studies before it is introduced into clinical practice for treatment of Inflammatory bowel disease.

## Acknowledgement

We authors thank the staffs of Department of Pharmacology and Department of Pathology, Gauhati Medical College and Hospital, Guwahati, for their help at various stages of the study.

**Funding:** None

**Conflict of interest:** None

**Ethical approval:** Institutional ethics committee.

## References

- Friedman S, Blumberg S. Inflammatory Bowel Disease. In: Kasper DL, Braunwald U, Fauci AS, Hauser SL, Longo DL, Jameson JL, editors. *Harrison's Principles of Internal medicine*, 18th Ed, McGraw-Hill; 2012:1776-1788.
- Podolsky DK. Inflammatory bowel disease. *N Engl J Med*.2002;347:417-429.
- Bouma G, Strober W. The immunological and genetic basis of inflammatory bowel disease. *Nat Rev Immunol*. 2003;3:521-531.
- Palmer K R, Penman ID: Disease of the alimentary tracts and pancreas. In: Davidson's principle and practice of medicine, Eds. Haslett C, Chilvers ER, Hunter JAA, Boon NA, 18th edn., Churchill Livingstone, UK, 1999,659-668.
- Kenneth M, Mc Quid MD: Alimentary tract. In: Current Medical Diagnosis and Treatment. 42nd edn., Eds. Tierney LM, Macphee SJ, Papadakis MA, McGraw Hill, Chicago, 2003,602-611.
- Berger J, Moller DE. The mechanism of action of PPARs. *Annu Rev Med*.2002;53:409-435.
- Ricote M, Li AC, Willson TJ, et al. The peroxisome proliferator-activated receptor-g is a negative regulator of macrophage activation. *Nature*. 1998;391:79-82.
- Faveeuw C, Fougeray S, Angeli V, et al. Peroxisome proliferator-activated receptor g activators inhibit interleukin-12 production in murine dendritic cells. *FEBS Lett*. 2000;486:261-266.
- Yang XY, Wang LH, Chen T, et al. Activation of human T lymphocytes is inhibited by peroxisome proliferator-activated receptor g (PPARg) agonists. *J Biol Chem*. 2000;275:4541-4544.
- Saez E, Tontonoz P, Nelson MC, et al. Activators of the nuclear receptor PPARg enhance colon polyp formation. *Nat Med*. 1998;4:1058-1061.
- Lefebvre M, Paulweber B, Fajas L, et al. Peroxisome proliferator-activated receptor g is induced during differentiation of colon epithelium cells. *J Endocrinol*. 1999;162:331-340.
- Girnun GD, Smith WM, Drori S, et al. APC-dependent suppression of colon carcinogenesis by PPARg. *Proc Natl Acad Sci USA*. 2002; 99:13771-13776.
- Sarraf P, Mueller E, Jones D, et al. Differentiation and reversal of malignant changes in colon cancer through PPARg. *Nat Med*. 1998;4:1046-1052.
- Gupta RA, Sarraf P, Brockman JA, et al. Peroxisome proliferator-activated receptor g and transforming growth factor-b pathways inhibit intestinal epithelial cell growth by regulating levels of TSC-22. *J Biol Chem*. 2003;278:7431-7438.
- Medhi B, Prakash A, Avti PK, Saikia UN, Pandhi P, Khanduja KL. Effect of Manuka honey and sulfasalazine in combination to promote antioxidant defense system in experimentally induced ulcerative colitis model in rats. *Indian Journal of Experimental Biology* 2008;46:583-90.
- Sanchez HM, Martín AR, Villegas I, Alarcon De La. Rosiglitazone, an agonist of peroxisome proliferator-activated receptor gamma, reduces chronic colonic inflammation in rats. *Biochem Pharmacol* 2005;69(12):1733-44.
- MacPherson BR, Pfeiffer CJ. Experimental production of diffuse colitis in rats. *Digestion*. 1978;17:135-50.
- Choudhary S, Keshavarzian A, Yong S, Wade M, Bocckino S, Day BJ, Banan A. Novel antioxidants zolimid and AEOL11201 ameliorate colitis in rats. *Dig Dis Sci* 2001;46:2222-30.
- Morris GP, Beck PL, Herridge MS, Depew WT, Szewczuk MR, Wallace JL. Hapten-induced model of chronic inflammation and ulceration in the rat colon. *Gastroenterology* 1989;96:795-803.
- Weir RF. A new use for the useless appendix in surgical treatment of obstinate colitis. *Med Rec* 1902;62:201.
- Elson CO, Sartor RB, Tennyson GS, Riddell RH. Experimental models of inflammatory bowel disease. *Gastroenterology* 1995;109:1344-67.
- Nakhai LA, Mohammadirad A, Yasa N, Minaie B, Infer S, Ghazanfari G, Zamani MJ, Dehghan G, Jamshidi H, Boushehri VS, Khorasani R, Abdollahi M. Benefits of Zataria multiflora Boiss in experimental model of mouse inflammatory bowel disease. *E CAM* 2007;4(1):43-50.
- Hidalgo MS, Martin AR, Villegas I, Lastra CA. Rosiglitazone, a PPARgamma ligand, modulates signal transduction pathways during the development of acute TNBS-induced colitis in rats. *Eur J Pharmacol* 2007;562(3):247-58.
- Ashraf Taye, Adel H. Saad. Role of Rosiglitazone as a Gastro protective Agent against Indomethacin-Induced Gastric Mucosal Injury in Rats. *Gastroenterology Research* 2009;2(6):324-32.
- Mohanty P, Aljada A, Ghanim H, Hofmeyer D, Tripathy D, Syed T, Al-Haddad W, et al. Evidence for a potent anti-inflammatory effect of rosiglitazone. *J Clin Endocrinol Metab* 2004;89(6):2728-35.
- Demirturk F, Aytan H, Caliskan A, Aytan P, Yener T, Koseoglu D and Yenisehirli A. The effect of rosiglitazone in the prevention of intra-abdominal adhesion formation in a rat uterine horn model. *Human Reproduction* 2006;21(11):3008-13.
- Diab A, Deng C, Smith JD, Hussain RZ, Phanavanh B, Lovett-Racke AE, Drew PD, Racke MK. Peroxisome proliferator-activated receptor-gamma agonist 15-deoxy-Delta(12,14)-prostaglandin J(2) ameliorates experimental autoimmune.
- Kawahito Y, Kondo M, Tsubouchi Y, Hashiramoto A, Bishop-Bailey D, Inoue K, Kohno M, Yamada R, Hla T, Sano H. 15-deoxy-D12,14-PGJ2 induces synovocyte apoptosis and suppresses adjuvant-induced arthritis in rats. *J Clin Invest* 2000;106:189-97.
- Shiojiri T, Wada K, Nakajima A, Katayama K, Shibuya A, Kudo C, Kadowaki T, Mayumi T, Yura Y, Kamisaki Y. PPAR g ligands inhibit nitro tyrosine formation and inflammatory mediator expressions in adjuvant-induced rheumatoid arthritis mice. *Eur J Pharmacol* 2002;448:231-8.