

IN VITRO STUDY OF SPONTANEOUS AND HISTAMINE INDUCED CONTRACTIONS IN PRE-ATRETIC PART EXCISED FROM A CASE OF COLONIC ATRESIA

Preeti Tyagi^{1,*}, Maloy B Mandal², A.N. Gangopadhyay³

¹Assistant Professor, Dept. of physiology, Hamdard Institute of Medical Sciences & Research, Jamia Hamdard, New Delhi.

²Professor, Dept. of Physiology, Institute of Medical Sciences, Banaras Hindu University, Varanasi, UP.

³Professor, Dept. of Pediatric Surgery, Institute of Medical Sciences, Banaras Hindu University, Varanasi, UP.

***Corresponding Author:**

E-mail: drpreetityagi@gmail.com

ABSTRACT

Atresia is the congenital obstruction with complete occlusion of intestinal lumen and responsible for 95% of congenital intestinal obstructions. Colonic atresia is a rare form of intestinal atresia. Because of its rarity, limited literature is available on management and outcome of this entity. Although new operative techniques and better perioperative managements have led to an improvement, but delay in intestinal motility recovery and long term decreased motility remained common problems in postoperative period. Most of the surgeons excise the atretic part and only few centimeter of just adjacent pre-atretic part. Most of the dilated pre-atretic part is not excised usually and considered as normal but study on its exact functional status is not available. This study was done on pre-atretic part of freshly excised specimen of a case of colonic atresia in vitro to know the functionality of this part which may be helpful to decide that it should be preserve or excise. After clearing of fecal matter, 2-3 millimeter wide and 15-20 millimeter long longitudinal strip was prepared and mounted in organ bath filled with Krebs Ringer solution continuously bubbled with 100% oxygen. Spontaneous contractions were observed with the frequency of approximately 3 peaks/ hour and amplitude of 27.23 gram per gram wet tissue. There was no response by lowest dose of histamine (0.1 μ M) while dose dependent increase in the contractile force by different cumulative concentrations of histamine (1, 10 & 100 μ M) was observed. It can be concluded that pre-atretic part is normal up to some extent especially in respect to the pacemaker activity and histaminergic pathway so it should be preserved. However, detailed functional and histopathological study on more number of cases as well as on control specimens by using different agonists and their blockers are needed.

Key words: Colonic atresia, Contractions, Histamine, In vitro study

INTRODUCTION

Atresia is a Greek word; “a” means no or without and “trasis” means orifice. Atresia is the congenital obstruction with complete occlusion of intestinal lumen and responsible for 95% of congenital intestinal obstructions.¹ Intestinal atresia can occur anywhere in the gastrointestinal tract. According to the anatomical location of intestinal obstruction, intestinal atresia is classified into duodenal atresia, jejuno-ileal atresia and colonic atresia.

Atresia of the colon is a relatively rare form of intestinal atresia with an incidence of 1:40,000 to 1:60,000 live births.² Similar to other types of atresia, colonic atresia is believed to be caused by an in utero vascular accident resulting in ischemic injury, likely after the return of mid gut to the coelomic cavity. Two third of colonic atresias are in the distribution of the inferior mesenteric artery (IMA). Previous study suggested that defects in the fibroblast growth factor 10 (FGF10) paths way may be involved.³ The child present with symptoms of intermittent persistent bilious vomiting, abdominal distention and/or delayed meconium passage.⁴

Surgical correction (primary resection and anastomosis) is the mainstay of therapy for atresia. Because of its rarity, limited literature is available on

management and outcome of this entity. Although new operative techniques and better perioperative managements have lead to an improvement,⁵ but delay in intestinal motility recovery and long term decreased motility remained common problems in postoperative period.⁶ Usually most of the surgeons excise the atretic part and only few cm of just adjacent pre-atretic part. Rest of the dilated pre-atretic part is not excise and considered as normal but study on its exact functional status is not available. Previous studies showed abnormalities of the myenteric ganglia, nerve growth factor, and ICCs (interstitial cells of Cajal) and correlated these with the causes of intestinal motility problems after surgical repair of this entity.^{7,8} Previous study on chick intestinal atresia model showed decreased number of protein gene product 9.5-positive fibers in both the circular muscle and sub mucous layers in dilated proximal segments. The number of nerve fibers positive for Vasoactive intestinal polypeptide, Substance-P, and Nicotinamide adenine dinucleotide phosphate-diaphorase also found to be decreased in the circular muscle layer in the same study. They proposed that abnormalities of the proximal dilated segment might be implicated in the postoperative decreased motility of the intestine in intestinal atresia cases.⁹ Because of non availability of functional study

on pre-atretic, dilated part of colonic atresia; this preliminary functional study was done on the available one case of colonic atresia, a very rare entity.

CASE AND METHOD OF CONTRACTION STUDY

A three day old female newborn was brought to the pediatric surgery OPD by her parents with complain of intermittent bilious vomiting and difficulty in passing stool. Blood group of child was B positive. After all routine investigations, colonic atresia type IIIa was diagnosed and exploratory laprotomy with ileoascending anastomosis was done.

Excised colon specimen (fig. 1) was quickly transferred to physiology lab for contraction study in a wide mouth bottle filled with pre-oxygenated Krebs Ringer solution. The composition of Krebs Ringer is (in mM) – Sodium Chloride (NaCl)-119, Potassium Chloride (KCl)-4.7, Calcium Chloride Dihydrate ($\text{CaCl}_2 \cdot 2\text{H}_2\text{O}$)-2.5, Potassium Dihydrogen Phosphate (KH_2PO_4)-1.2, Magnesium Sulfate Heptahydrate ($\text{MgSO}_4 \cdot 7\text{H}_2\text{O}$)-1.2, Sodium bicarbonate (NaHCO_3)-5 and Glucose-11. The specimen was kept in Krebs Ringer solution, continuously bubbled with 100% oxygen throughout experiment. After clearing of fecal matter, 2-3 millimeter wide and 15-20 millimeter long longitudinal strip was prepared. The strip kept in an organ bath with a glass tube and contractions were recorded with the help of force transducer, bridge amplifier and digitalized system Power Lab on a personal computer. The strip was placed under an initial tension of 0.5 g and then left to equilibrate for 60 minutes, with replacement of Krebs solution every 15 minutes. Only one colonic strip was examined for spontaneous contractions because the excised tissue was less and only one strip could be prepared. Further, the contraction of same colonic strip was recorded with the four different cumulative bath concentrations (0.1, 1, 10 & 100 μM) of histamine. This method was also used in our

previous experiments on Pouch colon associated with Anorectal malformations and Hirschprung diseases.^{10,11}

FINDINGS/RESULT

The muscle strip showed spontaneous contractions within 20 minutes of stabilization period. In 60 minutes recording of the colonic smooth muscle strip, the rate of spontaneous contraction was calculated to be approximately 3 peaks/ hour. The amplitude of peaks of spontaneous contractions was 27.23 gram per gram wet tissue. Actual recording showing the spontaneous contractions in colonic atresia is shown in fig. 2. The sample did not respond to 0.1 μM concentration of histamine, however, considerable responses were obtained with the other concentrations (figure 3A, 3B). On examination of histamine dose response curve it was observed that there was dose dependent increase in the contractile force and the contractile strength was 89.54 gram per gram wet tissue above the peaks of spontaneous contractions, when highest concentration of histamine (100 μM) was used (fig. 3B).

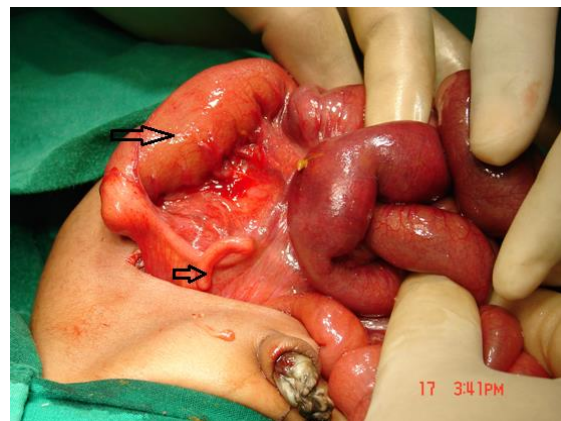


Fig. 1: Photograph showing a case of Colonic atresia during operation. Small arrow showing atretic part and big arrow indicates dilated pre-atretic part.

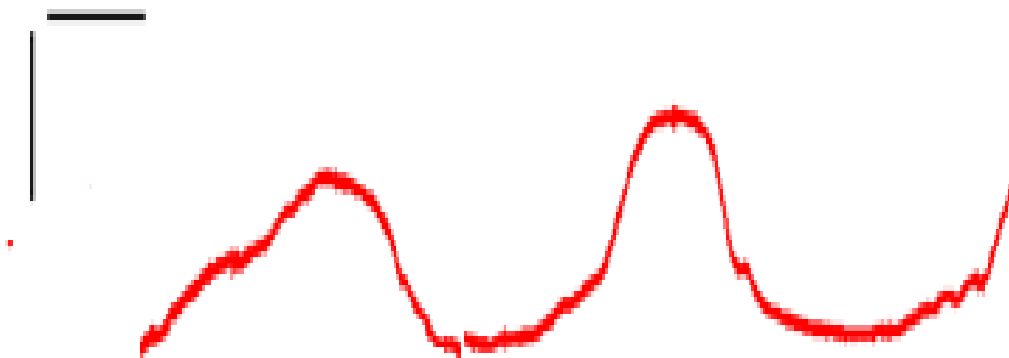


Fig 2. Actual recording of spontaneous contractions obtained from a colonic strip of pre-atretic part of colonic atresia. Vertical and horizontal calibration represents tension (1 g) and time (5 min) respectively.

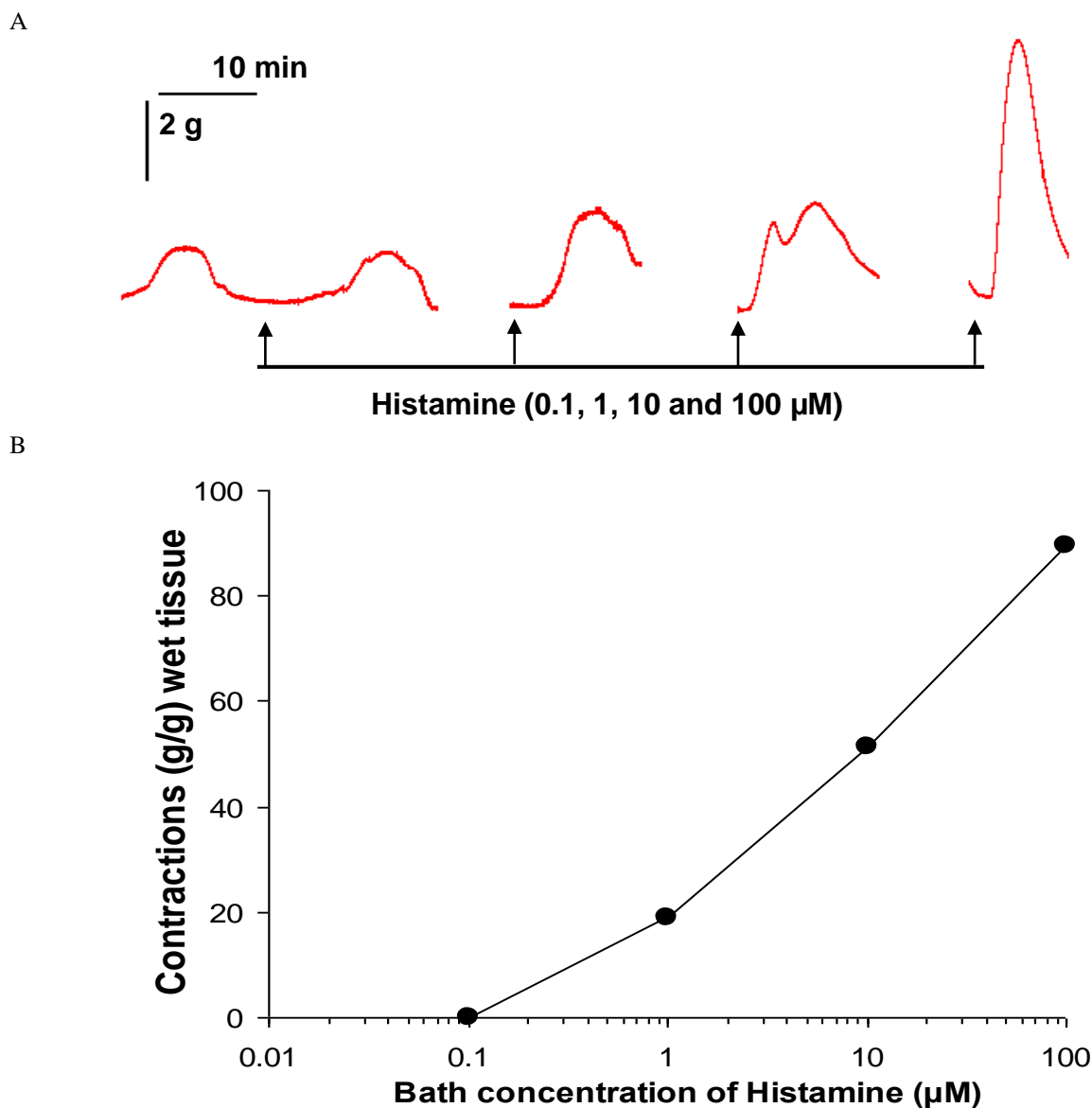


Fig. 3: A. Actual recording of responses to four different cumulative bath concentrations (0.1, 1, 10 & 100 μM) of histamine recorded from a strip obtained from pre-atretic part of a colonic atresia case. Please note that there was concentration dependent increase in the contractile responses and little effect on the spontaneous contractions with the 0.1 μM doses. Arrow (\uparrow) indicate the point of application of histamine. Vertical & horizontal calibration represents the tension (g) and time (min.) respectively. B. Histamine dose response curve.

DISCUSSION AND CONCLUSION

Colonic atresia is a rare surgical problem in neonates and intestinal motility problems are a major cause of morbidity postoperatively. The long term prognosis of surgical procedures with different degree of resection is variable and delay in intestinal motility recovery and long term postoperative decreased motility may occur.¹² Therefore, detailed study on the contractile mechanisms operating in intestinal atresia become necessary for formulating better surgical techniques. It was observed in previous studies that fetal intestinal obstruction

induces alteration of enteric nervous system development in human intestinal atresia. Enteric nervous system is most important in controlling the contractile movements of smooth muscles of intestine. Myenteric plexus has many neurons which secrete a number of neurotransmitter involved in intestinal contractions examples- Acetylcholine, Histamine, Serotonin, VIP, Substance-P, NO (nitric oxide) etc.¹³ Spontaneous activity is controlled by Interstitial Cells of Cajal (ICC). These cells are distinct mesenchymal type cells (stellate interstitial cells) which act as pacemaker cells of intestine that

send long branched processes into the intestinal smooth muscle. They are located in the outer circular layer near myenteric plexus in stomach and small intestine while at sub mucosal border of circular muscle layer in colon.¹⁴ Histamine is an important excitatory neurotransmitter involved in gastrointestinal motility. Histamine plays an important role in the pathophysiology of functional and inflammatory diseases. The four types of histamine receptors (H₁ to H₄) are known. The expression and extent of different subtypes of histamine receptors expression in gastrointestinal tract is not very clear. H₁ receptor seems to be most important for gastrointestinal contractility mechanism of histamine. Participation of H₁ receptors in mediating intestinal smooth muscle contraction has been documented in animals and human elsewhere.^{15,16}

In this case spontaneous contractions as well as histamine induced contractions are present. The tissue has been also showed dose dependent increase in the contraction with histamine. So it can be interpreted that the pre-atretic part is functioning normally up to some extent especially in respect to the pace maker activity and histaminergic pathway. Because of rarity of colonic atresia cases, even this functional study on single case can help in understanding of functional status of pre-atretic dilated part of colonic atresia, although detailed functional and histopathological study on more number of cases as well as on control specimens by using different agonist and their blockers are needed.

REFERENCES

- O'Neill JA Jr. Duodenal atresia and stenosis. In: O'Neill JA Jr, Rowe MI, Grosfeld JL. Pediatric Surgery. 5th ed. St Louis, Mo: Mosby; 1998.
- Davenport M, Bianchi A, Doig CM, Gough CS. Colonic atresia: current results of treatment. J R Coll Surg Edin 1990; 35:25-8.
- Fairbanks TJ, Kanard RC, Del Moral PM. Colonic atresia without mesenteric vascular occlusion. The role of the fibroblast growth factor 10 signaling pathway. J Pediatr Surg 2005;40:390-6.
- Hua-dong Chen, Hong Jiang, Anna Kan, Li-e Huang, Zhi-hai Zhong, Zhi-chong Zhanget al. Intestinal obstruction due to dual gastrointestinal atresia in infants: diagnosis and management of 3 cases. BMC Gastroenterology 2014; 14:108.
- García H, Franco-Gutiérrez M, Rodríguez-Mejía EJ, González-Lara CD. Co-morbidity and mortality during the first year of life in children with jejunoileal atresia. Rev Invest Clin 2006; 58:450-7.
- DallaVecchia LK, Grosfeld JL, West KW, et al: Intestinal atresia and stenosis: A 25-year experience with 277 cases. Arch Surg. 1998; 133:490-497.
- Wang X, Yuan C, Xiang L, Li X, Zhao Z, Jin X. The clinical significance of pathological studies of congenital intestinal atresia. J Pediatr Surg 2013;48:2084-91.
- Khen N, Jaubert F, Sauvat F, Fourcade L, Jan D, Martinovic J. Fetal intestinal obstruction induces alteration of enteric nervous system development in human intestinal atresia. World Journal of Gastroenterology 2012; 18:3099-104.
- Masumoto K, Suita S, Nada O, Taguchi T, Guo R, Yamanouchi T. Alterations of the Intramural Nervous Distributions in a Chick Intestinal Atresia Model. Pediatric Research 1999; 45, 30-7.
- Tyagi P, Mandal MB, Mandal S, Patne S C, Gangopadhyay A N. Pouch colon associated with anorectal malformations fails to show spontaneous contractions but respond to acetylcholine and histamine in vitro. J Pediatr Surg 2009;44:2156-62.
- Pandey S, Mandal MB, Gangopadhyay AN. In vitro study of contractile responses of bowel with Hirschsprung Disease. Natl J Physiol Pharm Pharmacol 2015; 5: 10-13.
- Nixon HH: Intestinal obstruction in the newborn. Arch Dis Child 1955; 30: 13-22.
- Gyton AC and Hall JE. General principles of gastrointestinal function. In: Gyton and Hall Textbook of Physiology. 12th ed. Elsevier pub. pp-756.
- Ganong W F. Gastrointestinal Motility. In: Review of medical physiology. 23rd ed. McGraw Hill publication. pp-470.
- Percy WH, Burton MB, Fallick F, Burakoff. A comparison in vitro of human and rabbit distal colonic muscle responses to inflammatory mediators. RGastroenterology. 1990; 99:1324-32.
- Bertaccini G, Morini G, Coruzzi G. Different mechanisms are responsible for the contractile effects of histaminergic compounds on isolated intestinal smooth muscle cells. J Physiol Paris 1997; 91: 199-202.